

What's Your Diagnosis?

Sarah Guengerich, Class of 2011

Lexi, 10 y/o FS Golden Retriever mix

Presenting complaint: hacking cough of three months duration

History:

- Lexi presented for an occasional hacking cough of three months duration.
- Physical exam: Lexi was alert and nervous. Her temperature was initially 103.2F, but was rechecked at 101.4F after the patient was acclimated to the exam room. She had a grade III/VI left-sided systolic heart murmur that radiated to the right. All other physical exam perimeters were within normal limits. A complete blood count and chemistry panel from the rDVM were within normal limits except for an elevated cholesterol at 425 mg/dL.
- Diagnostic plan: perform heartworm test and chest radiographs to rule-out cardiac disease

Heartworm test: SNAP test negative

Radiography:

- Thoracic Radiographs:

On the lateral view a large soft tissue mass associated with the heart base is present causing dorsal displacement of the trachea which is especially marked at the distal aspect of the trachea. The mass appears smooth and round with an approximate size of 11cm x 10cm x 9cm. The right cranial mainstem bronchus is compressed by the mass. On the VD view the mass markedly displaces the trachea and principle bronchi to the right. The right cranial lung lobe has an increased opacity seen as an unstructured interstitial pattern. There is a mediastinal shift dorsally and to the right.

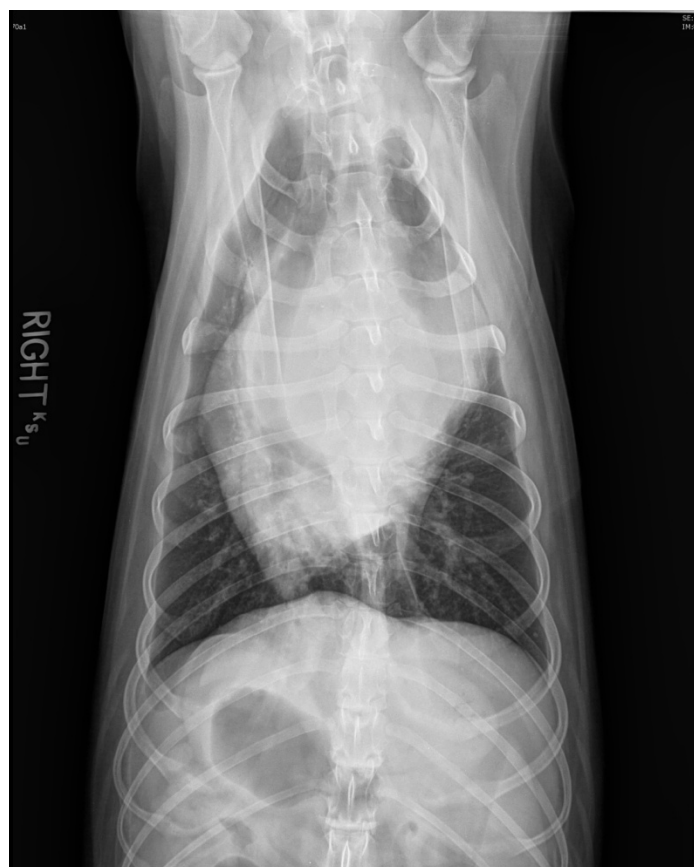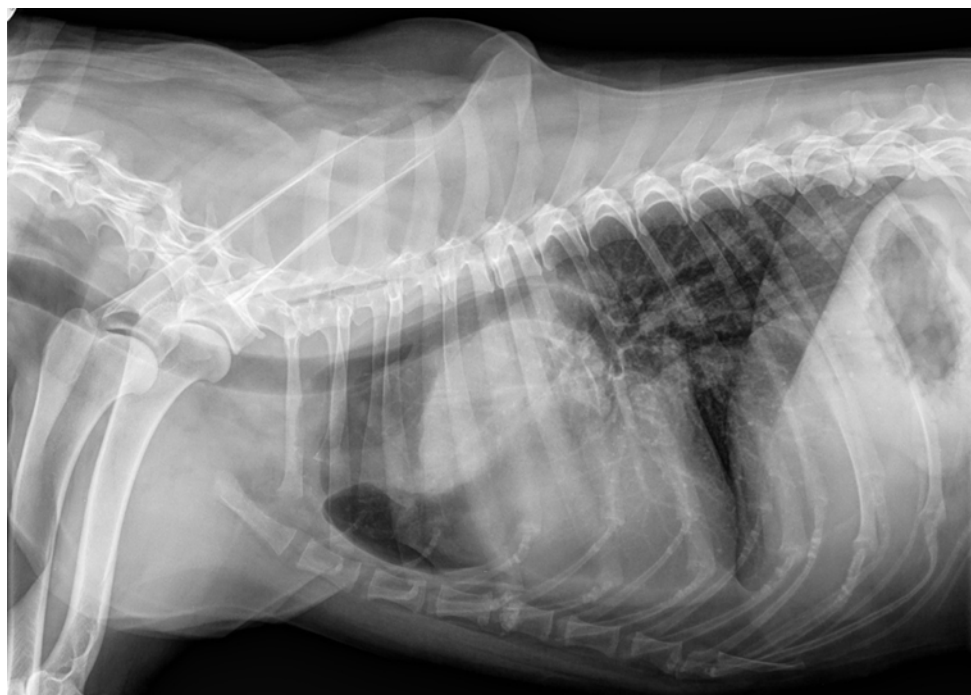Conclusion—A large heart base mass is present which is most consistent with neoplasia. An echocardiogram was recommended to further evaluate the mass's origin and structures possibly involved with the mass.

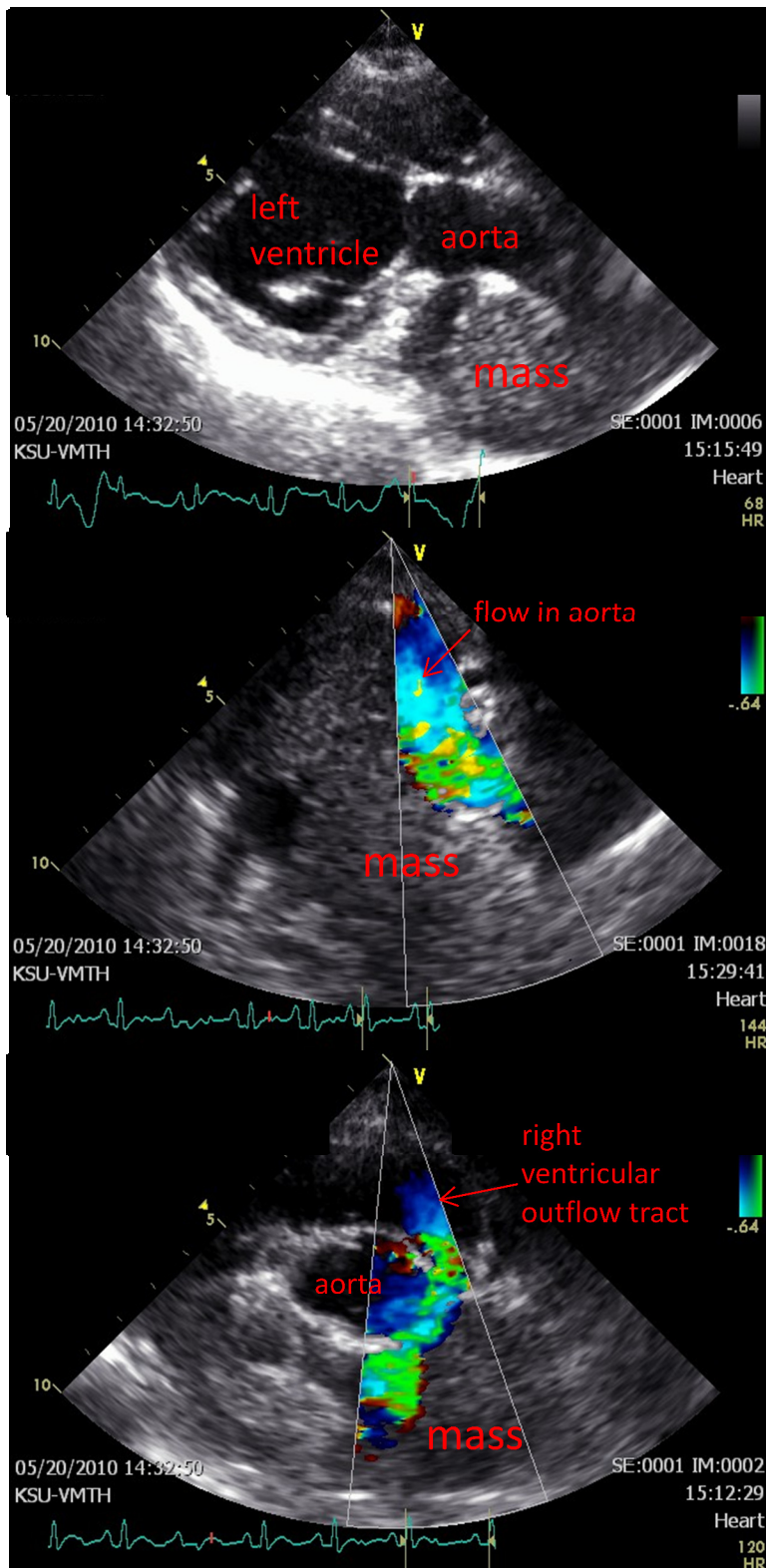
Echocardiography:

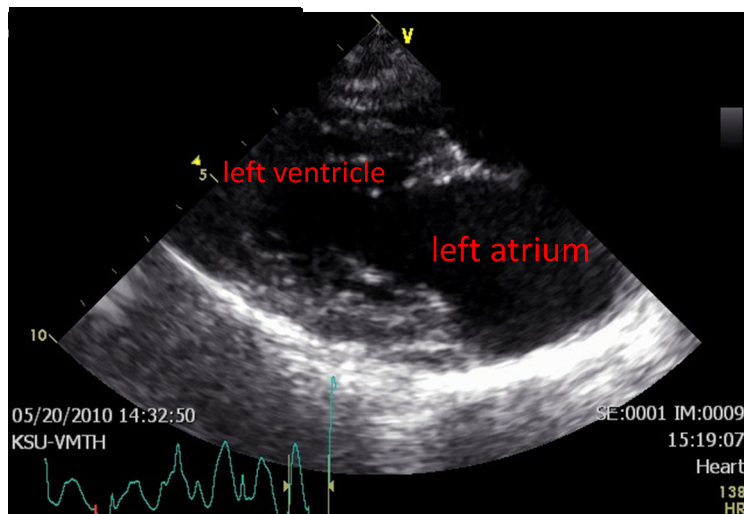
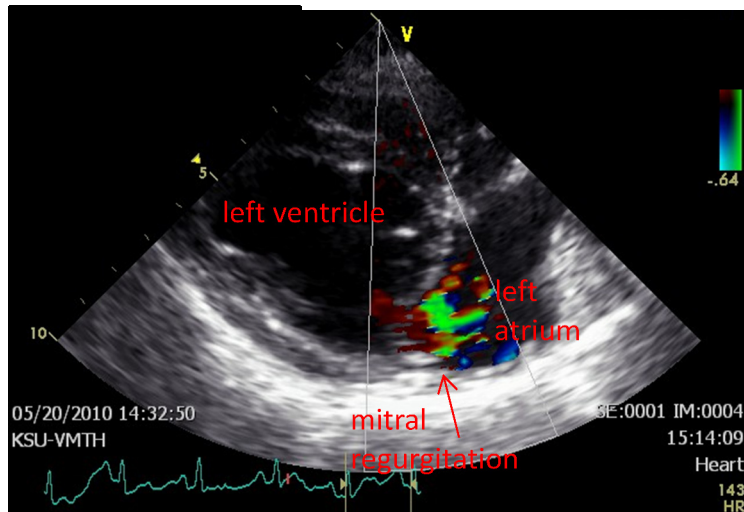
- Echocardiogram:

A large, homogenous mass encircles the aorta (echo image 1 and 2) and main pulmonary artery (echo image 3).

Mitral regurgitation and an enlarged left atrium, consistent with chronic degenerative mitral valve disease, are present (echo image 4 and 5).







Treatment:

- Surgery:

Lexi underwent a subtotal pericardectomy via a median sternotomy. The mass was visually confirmed to encircle the aorta and main pulmonary artery. A biopsy was not deemed to be an appropriate option due to the risk of life-threatening hemorrhage.

Outcome:

Lexi recovered well from surgery and was discharged two days after her surgery. At her recheck one month later, her owners reported that she continued to cough occasionally but had no other signs of illness related to her mass.

Conclusion:

Heart-based tumors in dogs most commonly consist of chemodectomas, hemangiosarcomas, lymphoma, fibrosarcomas, rhabdomyosarcomas, ectopic thyroid adenocarcinoma, or ectopic parathyroid adenocarcinoma. Because of the specific location of this mass which encircled the aorta, a chemodectoma was strongly suspected in Lexi's case. A review by Vicari et al. (JAVMA, August 2001) reported that dogs with heart-based masses that underwent pericardectomy had a mean survival time of 661 days compared to those that did not with a 129 day survival. The study found this to be independent of the presence of pericardial effusion at the time of diagnosis or surgery. Based on this review a subtotal pericardectomy was recommended for Lexi. This was determined to be the best option for addressing Lexi's disease process because chemodectomas are not responsive to chemotherapy and most often cannot be resected by the time their presence is known.