

KANSAS STATE UNIVERSITY

SPRING 2005

AnimalLIFE

VETERINARY MEDICAL TEACHING HOSPITAL

Inside

Ebony's
amazing tale

VMTH and
military form
an alliance
to save Ike

Final flight
for two
whooping
cranes

Back for more



The two words "animal" and "life" share the "L" because—just like our pets—they are a seamless part of our lives.

AnimalLIFE



Patrice and VMTH client, Dolly, a long coat Chihuahua

Our clients help us reach other animal lovers

We were proud to learn that the articles in our fall issue touched many of our readers. In fact, newspapers and radio stations across the state picked up the feature articles about Miles, Marvel and Sadie. One article even generated national media attention. "AKC Family Dog" magazine ran an article about Miles in the spring issue. The title is, "I Could Go for Miles". Please pick up a copy if you have a chance. If you missed it, you can read it in the May issue of "AKC Gazette". Again, special thanks to our VMTH clients for sharing their stories and for going the extra "miles" for their animals.

This issue holds something for everyone—from exotics to equine, from feline to the front line. First, we have the story of Ebony, an amazing 19-year-old cat whose remarkable owners faced his death and only asked what else could be done for him. Next, readers will be intrigued by Ike's story. It's not often that veterinarians are responsible for putting one of the Fort Riley Commanding General's troops back in action. But, it happened. Our final feature is about two endangered whooping cranes that were shot in western Kansas and arrived at the hospital in critical condition.

Because of this, I had the once-in-a-lifetime opportunity to interact with an endangered whooping crane. The bird was magnificent. Its piercing white plumage belied the darkness of its situation. He was weak, his breathing labored. He was straining to keep his head up. I'll never know the joy or pride or responsibility of healing; however, I could comfort the struggling bird. While zoological medicine veterinarians treated the bird's injured leg, I gently touched the palm of my hand to his sweeping neck. Within seconds, he rested his weight in my hand. The bird must have been confused: the same species that brought him down was now trying to save him.

We hope that these stories touch, teach and inspire you. They have us.

As always, please contact me with your pet's experience at our hospital or thoughts about our magazine. I truly appreciate hearing from you. And for those who have taken the time to email or call, you are right: I definitely have the best job in the world. 🐾

All the best,

Patrice Scott
Communications and Development Officer
Veterinary Medical Teaching Hospital
1700 Denison Ave., 103 Trotter Hall
Manhattan, KS 66506-5601
785.532.4046
email: pscott@vet.k-state.edu

SEEN & QUOTED

Any glimpse into the life of an animal quickens our own and makes it so much larger and better in every way.
—John Muir

AnimalLIFE

Contents

Pg. 5 Your Specialist

Dr. Laura Armbrust radiates enthusiasm for her specialty. She is one of only 264 board-certified veterinary radiologists in the nation.



Pg. 6 Out of the Blue

The annual migration of two endangered whooping cranes ended two states too soon. They were flying from Canada to Texas when they were hit out of the blue.

Pg. 10 From out of the shadows

There were no black-and-white decisions when it came to Ebony's healthcare.



Pg. 14 We like Ike

Maj. Gen. Dennis Hardy, commanding general of Fort Riley, turned to the VMTH when one of his mounts faced a career-ending injury. Learn how the two joined forces to save Ike.

Pg. 18 Referring Vet

Dr. Jeff Jacobson views the VMTH as an asset to his growing practice.



Pg. 19 The Schwopes loved animals, each other and the VMTH

Clients were so touched by a respected VMTH clinician that they gave a gift to the hospital 30 years after their last appointment.

About the Cover

After 23 days of not being able to hold her cat, Emilie Gahnstrom enjoys a tender moment at home with Ebony. The Gahnstroms were so committed to Ebony that they sought out the best medical care available. Ebony's story is on page 10. Photo credit, Dave Adams.

Editor

Patrice Scott
1700 Denison Ave.,
103 Trotter Hall
Manhattan, KS 66506-5601
785.532.4046
pscott@vet.k-state.edu

Photography

Instructional Technology Center
College of Veterinary Medicine
Kansas State University
Dave Adams
Patrice Scott
Personal family photos
Getty Images

Publisher

AnimalLIFE is published by the
Veterinary Medical Teaching
Hospital at Kansas State
University, Manhattan, KS 66506.
For advertising information
contact Patrice Scott at
785.532.4046.

All rights reserved.

Contents of this
magazine may not be reproduced
in any manner without the written
consent of the publisher.

View

President Kennedy's quote symbolizes our vision and guides us as we work toward becoming the finest Veterinary Medical Teaching Hospital in the nation. Here are just a few examples of how we are turning our shared vision into reality.

In the last issue of "Animal**LIFE**", we announced plans to renovate the Small Animal Intensive Care Unit (SAICU) and detailed how this facility will serve critically ill patients in the Midwest. We are pleased to tell you that construction should begin this summer. We send an enormous thank-you to the Pet Trust for its \$100,000 donation to the SAICU renovation and to Pfizer Animal Health for its \$100,000 commitment for the renovation of our small animal dental suite. It is one of four specialty areas that will be upgraded as part of the SAICU renovation. And, we have more great news!

We are thrilled to announce that the College of Veterinary Medicine will begin construction of a satellite specialty and critical care hospital in Omaha, Neb., later this summer. The hospital will be connected to the existing emergency clinic, owned by local veterinarians, by a breezeway to facilitate transport of patients between the clinic and hospital. The breezeway will be a physical representation of the bridge that will connect patients, clients, referring veterinarians, students, faculty and alumni in an unprecedented way. We are proud of this partnership, and we sincerely appreciate the Omaha area veterinarians' enthusiasm and support for this project. We look forward to working with all veterinarians in the area to provide exceptional care for animals and their owners, and we join our students in being excited about this new opportunity to provide clinical training.

Another improvement in the months since our last issue is the arrival of digital radiography. This X-ray system works much like a digital camera in that images are immediately available for evaluation. And, images can be viewed from any monitor in the hospital, making it much easier to show radiographs to clients. Read more about this in the faculty profile on Dr. Laura Armbrust, one of our radiologists.

Amidst all of this change is our continuing commitment to quality healthcare. That's what you will read about in the articles highlighting Ebony, the whooping cranes and Ike, a member of Fort Riley's Commanding General's Mounted Color Guard. According to Maj. Gen. Dennis Hardy, Ike has done an outstanding job serving his country. When we were informed that Ike's military career was in jeopardy because of his condition, our mission became clear: return Ike to active duty. I hope you enjoy reading about how our exceptional clinicians and students partnered with military personnel to save Ike's career.

Thank you for helping us build a road for the next generation of veterinarians. This is an exciting time for the Veterinary Medical Teaching Hospital and we are pleased to share that excitement with you. Thank you for supporting our hospital and thank you for caring about animals. 🐾

Warm regards,



Roger B. Fingland, DVM, MS, MBA
Diplomate, ACVS
Professor and Director
Veterinary Medical Teaching Hospital

Photo by Brennan Engle



Ike and Dr. Roger Fingland

"There is an old Chinese saying that each generation builds a road for the next. The road has been built well for us, and I believe it incumbent upon us, in our generation, to build our road for the next generation."

—John F. Kennedy

Dr. Laura Armbrust • Radiologist

by Patrice Scott

Image is everything. If you are uncertain about that, ask a radiologist.

A radiologist in the classic sense is “a person skilled in the diagnostic and/or therapeutic use of X-rays and other forms for radiant energy.” Today’s radiologist deals with multiple imaging modalities including

Computed Tomography (CT scan), Ultrasound, Magnetic Resonance Imaging (MRI), nuclear medicine and radiographs. One radiologist who has mastered them all is Dr. Laura Armbrust, assistant professor of radiology.

“Radiologists work closely with other veterinary specialists or general practitioners to improve the quality of patient care,” Dr. Armbrust says. “We provide a service to help with the accurate diagnosis of the patient. We also make recommendations on additional diagnostic procedures if necessary to confirm a diagnosis. This allows the veterinarian/specialist providing the primary patient care to make the most informed decision regarding prognosis and treatment.”

The opportunity to work with a variety of technologies and patients drew Dr. Armbrust to this dynamic field. It especially appealed to her interest in anatomy and the vast differences among species. “I once had to research the thickness of the stomach of an anteater in order to determine if my Ultrasound findings were normal or abnormal,” she says. “The variety of animals we treat keeps the job interesting.”

Dr. Armbrust enjoys helping a multitude of animals as a radiologist. However, she sometimes misses the daily client/patient interaction she had while working in a mixed animal practice in Wisconsin following her graduation from K-State in 1996. A decision to take an advanced rotation in radiology during her senior year exposed her to the possibilities of becoming a specialist. In 1998, she returned to K-State to begin a three-year residency.

“I had great mentors who encouraged me to pursue my interest in




Photo by Brennan Engle

radiology,” she says of Drs. David Biller, Susan Kraft and James Hoskinson. “I really wanted to specialize. I wanted to be exceptional at one thing.” Exceptional she is. Dr. Armbrust is one of only 264 board-certified veterinary radiologists in the United States.

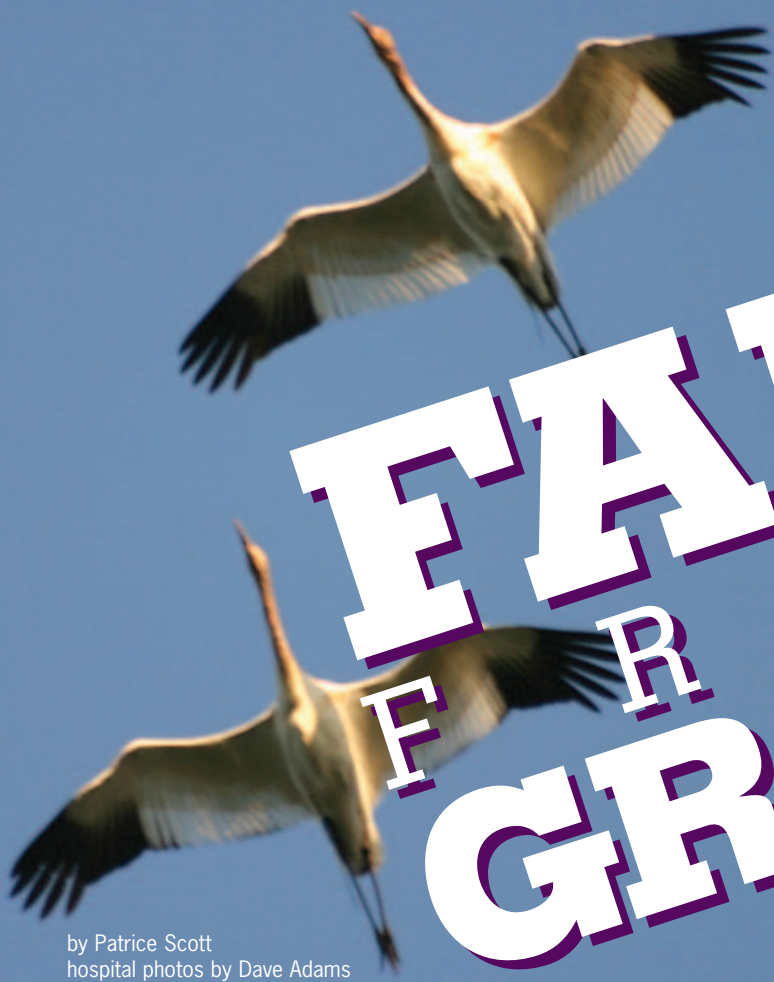Dr. Armbrust appreciates the support she received from her mentors. Now, it’s her turn to support students and residents. “Dr. Armbrust is always willing to stop whatever she might be doing to help a student,” says senior student Kimberley Parkes. “She is very intelligent, patient and has a tremendous amount of compassion for everyone. I really enjoyed my radiology rotation.”

This spring, the hospital converted to a digital imaging system. A digital radiograph is taken and the image appears on a computer monitor. This new system is advantageous because it reduces patient exposure to radiation, the image is available immediately and there is no time lost waiting for the film to be processed. “The new digital system is exceptional and allows our hospital to be at the forefront of diagnostic imaging in veterinary medicine,” Dr. Armbrust says.

When she’s not on clinics or teaching students, Dr. Armbrust is conducting research. Since CT and MRI are relatively new in veterinary medicine, some of her clinical research projects focus on these imaging modalities. Currently, she is doing a study that involves a comparison of radiographs to CT for detection of pulmonary metastases in cancer patients. She also has an interest in using MRI for detection of diseases that cause bone marrow abnormalities.

At the end of the day, Dr. Armbrust hopes her work as a radiologist has been helpful to students and other veterinarians and that ultimately she has made a difference in the lives of animals and their owners.

Dr. Armbrust and her husband, Trent, live in Manhattan with their children Bryan, 7, and Emily, 5. 🐾



by Patrice Scott
hospital photos by Dave Adams

It was Saturday, Nov. 6, 2004, opening day of goose and sandhill crane hunting season, when landowners near Great Bend, Kansas, discovered two endangered whooping cranes had been shot.

Whooping cranes grace the Kansas sky each fall during their 2,000-mile migration from Canada to Texas. But two birds in last year's flock only made it halfway.

It was Saturday, Nov. 6, 2004, opening day of goose and sandhill crane hunting season, when landowners near Great Bend, Kan., discovered two endangered whooping cranes had been shot. The U.S. Fish and Wildlife Service was alerted and soon biologists were at the scene, quickly establishing contact with Dr. James Carpenter, professor of zoological medicine at the Veterinary Medical Teaching Hospital (VMTH).

Dr. Carpenter and the biologists were in contact throughout the day as arrangements were made to transport the injured birds from near Quivira National Wildlife Refuge to the VMTH. Senior student Kristen Yates was on call that night.

"Dr. Carpenter called and informed me of the situation, briefed me on the birds' medical conditions and said that we should be prepared for them to arrive around 10 p.m.," Kristen says. "We have great resources at the hospital, but even our extensive supplies didn't include a sling for a bird that stands five feet tall. We gathered various items and fashioned them into a sling. It was quite the engineering feat."

When the injured cranes finally arrived, there was a swarm of activity. The birds were in critical condition. Eleven people, including faculty and staff, split into two groups to provide emergency treatment. For three intense hours, the teams worked to save the birds. (The birds are referred to as Whooper 1 and Whooper 2.)

"One bird's leg (Whooper 1) was essentially amputated by the shot," Dr. Carpenter says. "Its left leg was dangling by one tendon, so we had to amputate. The bird had lost a significant amount of blood, was in shock, was dehydrated and depressed."

Whooper 2 suffered from a mid-shaft fracture of the left humerus (broken wing). Even worse, it was an open wound. That night, doctors performed a minor surgery on the bird to clean and stabilize the fracture. If it survived, another surgery would be necessary.

Emergency therapy for both birds included: IV fluids with dextrose, an energy source; vitamin B to treat anemia due to blood loss; antibiotics to treat infection; tube feeding; and analgesics for pain control. Radiographs revealed that

By Sunday, Whooper 2 showed improvement. He underwent surgery where stainless steel pins were implanted in the bone to repair the broken wing. "While the condition of this bird was improving, the prognosis remained guarded."

Whooper 1 had four pellets lodged in its body.
Whooper 2 had 11 pellets.

By Sunday, Whooper 2 showed improvement. He underwent surgery where stainless steel pins were implanted in the bone to repair the broken wing. "While the condition of this bird was improving, the prognosis remained guarded," Dr. Carpenter says. "Because of the value that these birds had to the genetics of the species, we were obligated to do everything we could."

That included a trip to the hardware store on Sunday. Dr. Carpenter devised a plan to create a prosthetic limb out of PVC pipe for the crane.

The birds were members of the world's only naturally migrating flock of whooping cranes. There were roughly 215 birds in that flock, and they typically travel in family units. The total population in the world is less than 500 birds.

Senior student Brandy McGreer came on duty that Sunday morning. "These birds are really social and travel in flight groups," she said. "It was so sad to learn that a few of the birds stayed in the field for quite some time where the injured birds went down."



Dr. James Carpenter, professor of zoological medicine at VMTH.

Whooping cranes earned their name because of their loud, distinctive call that can be heard up to two miles away. This bugle is created by resonance in the bird's trachea. The trachea is convoluted (coiled) within the sternum and is five feet long—that's as long as the bird is tall. Whoopers, as they are commonly referred to, are the tallest birds in North America.

Despite three days of intensive care, the condition of Whooper 1 had not changed. "He never responded to treatment, Dr. Carpenter says. "His activity level and his attitude never improved. This is a wild bird, and it was not normal for him to be as compliant as he was when we were treating him."

Dr. Carpenter would know the normal behavior of a whooping crane because he specialized in their care.

Before coming to the VMTH, he spent 15 years at the Patuxent Wildlife Research Center (U.S. Fish and Wildlife Service) in Laurel, Md. The center is a national and international leader in wildlife research focusing on complex biological issues. While there, Dr. Carpenter received a national award for the conservation and preservation of endangered wildlife in North America. He planned to send the birds to Patuxent if they survived.

continues on next page

FACT:

The whooping crane is one of 388 animals and 599 plants in the U.S. protected by the Endangered Species Act. The bird first appeared on the list on March 11, 1967, one year after the Endangered Species Protection Act was passed. The whooper is considered by many to be the poster child for the Endangered Species Act.

According to the U.S. Fish and Wildlife Service, "an endangered species is one that is in danger of extinction throughout all or a significant portion of its range. A threatened species is one that is likely to become endangered in the foreseeable future."

In 1941, the last migrating flock of whooping cranes had dwindled to 15 birds due to habitat loss and hunting. Today, the total population has grown to nearly 500 birds because of federal protection and conservation efforts.

Wild populations of whooping cranes feed and roost in wetlands and upland grain fields. Because of this, federal and state wildlife management lands in five states—Idaho, Kansas, Nebraska, Oklahoma and Texas—are designated as critical habitat for whoopers.

Including the whooping crane, there are 13 animals and two plants in Kansas protected under this legislation.

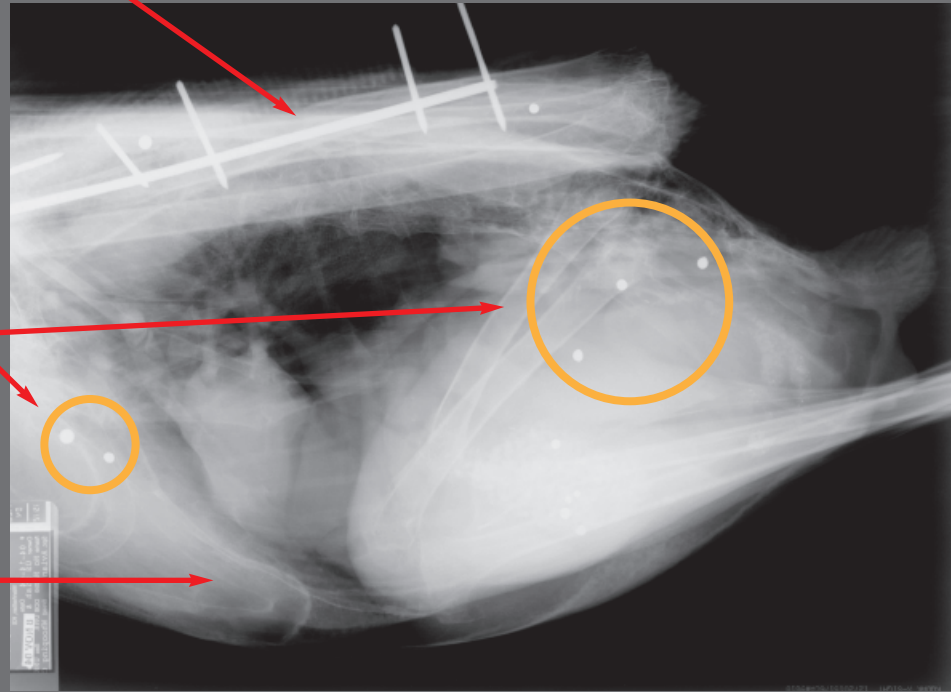


Every picture tells a story



FALL GRACE

- The radiograph below is of Whooper 2, later named “Kansas”. This shows the location of a surgical implant used to repair the bird’s broken wing. Whoopers have an impressive seven-foot wingspan and weigh an average of 16 lbs.



- The small white circles are shot pellets. Whooper 2 had 11 lodged in his body. Seven are visible in this view. The bird may have ingested two or three pellets (far right circle), which Dr. Carpenter says is not uncommon. The birds sometimes eat them when they mistake them for grit, which is used to help grind up food in their stomach.

- A section of the bird's trachea.

In many cultures, especially in the Asian countries, cranes are revered and symbolic. In Japan, cranes are symbols of a long life and happy marriage. In Vietnam, cranes are believed to carry the souls of the dead to heaven.

If cranes escort people on their spiritual journey, perhaps they do the same for other cranes. And if that is the case, Whooper 1 flew home with friends when he died quietly Tuesday night. “We did everything we could for him,” Dr. Carpenter says. “His injuries were so severe, that ultimately nature took its course.”

Hope remained for Whooper 2, named “Kansas” by his future caregivers at Patuxent. “Kansas” steadily improved despite intermittent respiratory problems. Dr. Carpenter suspected an aspergilloma, a localized fungal infection that occasionally occurs in birds that are stressed and debilitated. Dr. Carpenter believed that the infection most likely settled in the bird's trachea. This is particularly troublesome because if antibiotics didn't cure the infection, surgery would be almost impossible.

Time was of the essence. “Kansas” was stable, and Dr. Carpenter recommended that the bird be transported to Patuxent because the facility already housed numerous whooping and sandhill cranes. He believed “Kansas” would do better in a large open air enclosure adjacent to other cranes.

It's not often that a bird needs an airplane to fly, but “Kansas” did. The Kansas Department of Wildlife and Parks used its plane on Nov. 18 to fly “Kansas” to the research center in Maryland. “That was really an outstanding contribution by KDWP to help this bird,” Dr. Carpenter says.

Senior student Tim Harmon helped coordinate the bird's transport from Manhattan to Maryland. “We put a lot of work and time into his care,” Tim says. “This was the only place that I could get this kind of experience. It was exciting to have the opportunity to help one animal for the conservation of the species.”

“Kansas” survived the flight and for the first few weeks did well at Patuxent. On Dec. 9, Dr. Carpenter received word that “Kansas” had died. Those closest to his care suspect an aspergilloma claimed his life. A postmortem exam will be performed at the National Forensic Laboratory in Ashland, Ore. Results have not been released as of this writing.

“I was saddened by the news that “Kansas” had died,” Kristen said. “But I learned a great deal from these cases. I learned about crane medicine and physiology but also about the patience, creativity and teamwork that it takes to work with an exotic, wild species.” 🐾



Top (from left to right): Senior student Brandy McGreer and Dr. Christal Pollock, assistant professor of zoological medicine, feed an injured whooper while Dr. Jim Carpenter holds the bird. Above: On Nov. 18, the Kansas



Department of Wildlife and Parks airplane prepares to take off for Patuxent Wildlife Research Center in Laurel, Md. Above right (from left to right): Dr. Carpenter carries "Kansas" from the VMTH vehicle to the airplane with the help of senior student Tim Harmon, center. (Tim's parents are Gary and Cathy Harmon both veterinarians in Andover, Kan.) Dan Mulhern (right) is with the U.S. Department of Fish and Wildlife Service.

Editor's Note:


A group of seven hunters admitted to shooting the birds. They claimed to have mistaken them for sandhill cranes. A report on the incident has been filed with the U.S. Attorney's Office. If charges are filed against the hunters, the maximum penalty under the Endangered Species Act is one year in prison and a \$100,000 fine.

All photographs of Whooping Cranes in the wild are courtesy of Operation Migration, a non-profit organization. For information about Operation Migration go to: www.operationmigration.org.

EBONY'S TALE

by Patrice Scott
photos by Dave Adams

Everyone involved in Ebony's healthcare understands that he has lifelong medical issues that require skilled management. The doctors and staff have tremendous respect for Bill and Emilie and the choices they've made for Ebony.



"Code 10," a voice shouted in the Small Animal Intensive Care Unit (SAICU). A patient was in trouble.

The patient was Ebony, a 17-year-old black domestic longhair cat. His breathing stopped, then his heart. Doctors and SAICU staff slid Ebony from his cage and started CPR. Because of their fast action, the monitoring equipment that once was still, blinked with life.

Losing Ebony was Bill and Emilie Gahnstrom's greatest fear. They struggled with the decision to bring Ebony to the Veterinary Medical Teaching Hospital (VMTH) because of an experience years ago with a veterinarian on the west coast. "I was scared to death," Emilie admits. "I was afraid of what might happen to Ebony. I had already lost two cats that I hoped would live to be 100."

The experience overshadowing their decision was the painful and unexpected loss of Emilie's beloved cat, Shadow. In 1986, Bill was an officer in the navy and they were stationed in California. Emilie took Shadow to a veterinarian for a routine procedure. It was there that Shadow died unexpectedly. The couple was in shock at the death of their perfectly healthy cat. "That kind of experience stays with you," Bill says.

But Ebony needed help. He was being treated for hyperthyroidism by his veterinarian, Dr. Heidi Bradford, when a lump appeared in his neck. It was affecting his quality of life. Every few months, Emilie took Ebony to Dr. Bradford to aspirate the growth. As the lump increased in size, so did the frequency of his visits. They became weekly. "It got to the point I didn't even make an

The tests revealed

that Ebony had a host of medical problems. “Ebony had mild chronic renal failure, a heart condition and was hyperthyroid. The cyst in his neck was large and possibly malignant. The changes in his heart were consistent with hyperthyroidism.”

—Dr. Deb Hall-Fonte

appointment,” Emilie says. “I’d just call and say Ebony was on the way.”

Dr. Bradford did all she could for Ebony. “We were draining the lump in his neck and it was filling faster and faster,” she says. “We were not gaining ground. We kept suggesting that they take Ebony to K-State to be evaluated by a specialist. K-State was the right place for him.”

In the end, Emilie faced her fears and did what was best for Ebony. On June 16, 2003, Bill, Emilie and Ebony made the one-hour drive from their home in Topeka, Kan., to the VMTH.

Dr. Deb Hall-Fonte, medicine resident, examined Ebony. “When Ebony presented, he was uncomfortable and very thin,” Dr. Hall-Fonte says. “The mass in his neck was plum-sized, but we suspected it was much larger and intertwined with deeper structures. We ordered a battery of tests – blood work, radiographs, an Ultrasound, nuclear scan and echocardiogram because we had to determine what we were dealing with, and we wanted to thoroughly evaluate Ebony.”

Bill remembers that day. “Dr. Hall-Fonte looked at us and said, ‘We don’t know exactly what is wrong with Ebony right now, but we are going to find out.’”

The tests revealed that Ebony had a host of medical problems. “Ebony had mild chronic renal failure, a heart condition and was hyperthyroid,” says Dr. Hall-Fonte. “The cyst in his neck was large and possibly malignant. The changes in his heart were consistent with hyperthyroidism.”

Once Dr. Hall-Fonte had a complete picture of Ebony’s condition, she presented the Gahnstroms with two possible courses of action. “We could treat Ebony medically or surgically. Both options had inherent benefits and risks, but the decision was made to surgically remove the cyst.”

Dr. Meredith Esterline, surgery resident, outlined the risks of the procedure. “The first possible complication is laryngeal paralysis that occurs when the larynx doesn’t open appropriately to allow air to move to the lungs. The second possible complication is hypoparathyroidism. This can cause problems with calcium regulation.”



The Gahnstroms appreciated the information they received. “The doctors used the appropriate medical terms and explained things to us in such a way that it made sense to us. It wasn’t that we heard them, it was that we understood them,” Bill says.

At noon on June 20, 2003, Ebony underwent surgery. During the two-hour operation, Dr. Esterline removed a five-inch, fluid-filled mass from Ebony’s neck. “It was an extensive surgery. Very delicate,” Dr. Esterline says. “The mass was large, and it was attached to the trachea and to the esophagus.” Senior student Misty Gore was on the surgery rotation and vividly remembers the events of that day. “That surgery was tedious,” she says.

At 2:30, Ebony was moved to the SAICU. Entries in Ebony’s medical records detail his Code 10. “Extubation (removal of the tube in his trachea). Cat chewing, picking up head and swallowing. Cat arrested (respiratory, then cardiac). Reintubated, oxygen supplementation. Patient revived – heart started functioning, started to breathe, pressures stabilized.”

“It was extremely stressful,” Dr. Esterline says of Ebony’s episode. “We were able to get him reintubated and resuscitate him.” Misty recalls that alarming event. “So many people were pulling for Ebony that we weren’t

Above: Ebony walking on a railing at home.

Left: So happy together. Emilie, a master gardener and volunteer, at home with Ebony and Bill, a mathematics and statistics instructor at Washburn University.



Front row, from left to right: Dr. Meredith Esterline, Misty Gore and Ebony and Dr. Hall-Fonte. Back row: Brian Pulkrabek, Dana Parvin and Graham Burns.

about to let him go," she says. "I just thought to myself, 'After all of this, you can't go now.'"

Dr. Hall-Fonte and Dr. Esterline immediately suspected laryngeal paralysis. An emergency tracheostomy was performed to allow Ebony to breathe.

Bill and Emilie were informed that Ebony had indeed experienced a post-op complication. "We knew going in what the risks were," Bill says. "They expected challenges and briefed us on that. There really were no surprises."

Emilie wanted to focus on what could be done for Ebony. "We asked them what they could do. When they told us, we said 'go for it,' Emilie says. "Ebony was at K-State. He was in the best hands, and the doctors knew exactly what he needed. After they removed the cyst, Ebony was healthy. I wasn't going to lose him because he couldn't breathe. We could fix it."

On June 27, one week after his first operation, Ebony went to surgery to correct the laryngeal paralysis. "We used a suture to prop open the airway," Dr. Esterline says. "The surgery went precisely as planned." On July 2, Ebony went home.

Ebony's primary medical problem was treated surgically. His ongoing medical conditions were controlled through medications and intensive monitoring. Then the second post-op complication appeared: hypocalcemia, which is caused by hypoparathyroidism. Fortunately, this condition resolved within a couple of months on medical therapy.

However, during a visit in October, four months after his surgeries, Dr. Hall-Fonte discovered a small cyst on Ebony's neck in the same location as the one that was removed. Bill and Emilie decided to monitor it.

In 2004, Ebony returned for rechecks in April and December. Dr. Esterline was amazed when she saw Ebony in April. "I couldn't believe how great he looked," Dr. Esterline says. "He looked like an 8-year-old cat. He'd

Dr. Bradford finds advanced medicine has helped her p because we wanted him to receive t

put on weight and was healthier than he'd probably ever been." But the "new" cyst was still there.

At his appointment in December, the cyst was noticeably larger. "The cyst increased in size dramatically and was attached to underlying tissue," Dr. Hall-Fonte says. "I told Bill and Emilie that it was time for us to make another decision. I impressed upon them that age is not a disease."

Emilie decided to be proactive. "I didn't want to face that large lump again. It had grown from pea- to walnut-sized over the course of months," Emilie says. "If you trust someone, you stay with them. We knew that K-State was the best place for Ebony."

They did decide, however, to have the operation after the holidays. This time, the situation was eerily reminiscent of the death of Ebony's brother, Ivory. "We woke up on Christmas morning 1999 and Ivory was having trouble breathing," Emilie says with sadness as if it happened yesterday. "I called our vet, but it was Ivory's time to go. He died in my arms."

On Jan. 11, 2005, Ebony underwent a third surgery. "Although Ebony was 19-years-old, he was a much better surgical candidate than he had been two years earlier," Dr. Hall-Fonte says. "He did so well that he went home the next day."

The histopathology from the third surgery, unlike the first, confirmed that Ebony had cancer, thyroid carcinoma. There were no clean margins, meaning cancerous tissue remained. The next action was to attack the remaining cancer with nuclear medicine. It would require Ebony to be in isolation for 13 days.

Six weeks after his third surgery, Ebony received one subcutaneous injection of Radioactive Iodine I-131. It was two-and-a-half-times the normal dosage. "Ebony's dosage was so much higher because we were treating cancer," Dr. Hall-Fonte says. "He did fantastic. He was discharged the first day he was eligible to go home."



Ebony won five ribbons at a Topeka cat show three months after his first two surgeries.

relief in the fact that
patient. "We sent him to K-State
the best care available, and he did."

Emilie was elated when Ebony could finally go home, but there was a hitch: Ebony was radioactive. Of the four conditions of his release, the Gahnstroms only had a problem with one—contact. "We couldn't hold him or sleep with him or let him sit on our laps for 10 days," Emilie says. "Oh, that part was terrible. I had to put signs in all of the chairs so Bill and I would remember not to let Ebony sit with us."

Everyone involved in Ebony's healthcare understands that he has lifelong medical issues that require skilled management. The doctors and staff have tremendous respect for Bill and Emilie and the choices they've made for Ebony. "Bill and Emilie knew all the risks that were involved but were so committed to Ebony that they did whatever needed to be done for him," Dr. Esterline says.

Dr. Bradford finds relief in the fact that advanced medicine has helped her patient. "It is a real comfort knowing that Ebony is getting the best medicine possible," she says. "We sent him to K-State because we wanted him to receive the best care available, and he did."

Bill, who admits he is a demanding person, respects the teaching hospital. "The great thing about the hospital is that they have great resources, gifted people and they bring them together," Bill says. "Our experience was overwhelmingly positive in every respect. The hospital is professionally run, but what really surprised us is how much they care. We didn't expect that. Students who had moved on to other rotations in the hospital would seek us out just to say hello. It happened time and time again."

On April 7, Bill and Emilie received good news from oncology. "Great news!" Dr. Hall-Fonte says of the nuclear scan results following the I-131 treatment. "There is no evidence of cancer." Emilie was overjoyed. "I could fly home," she says. "I don't even need a car I'm so happy."

So why did the Gahnstroms do all of this: three surgeries, an I-131 treatment, a total of 23 days they couldn't hold Ebony, medical tests, and daily trips to the hospital for visits when Ebony was in SAICU? Ebony's medical conditions are complicated, but their answer is simple. "We love him," Emilie says. "He is our baby."

Looking back, Emilie says she would have done one thing differently. "I would have taken Ebony to K-State sooner." 🐾

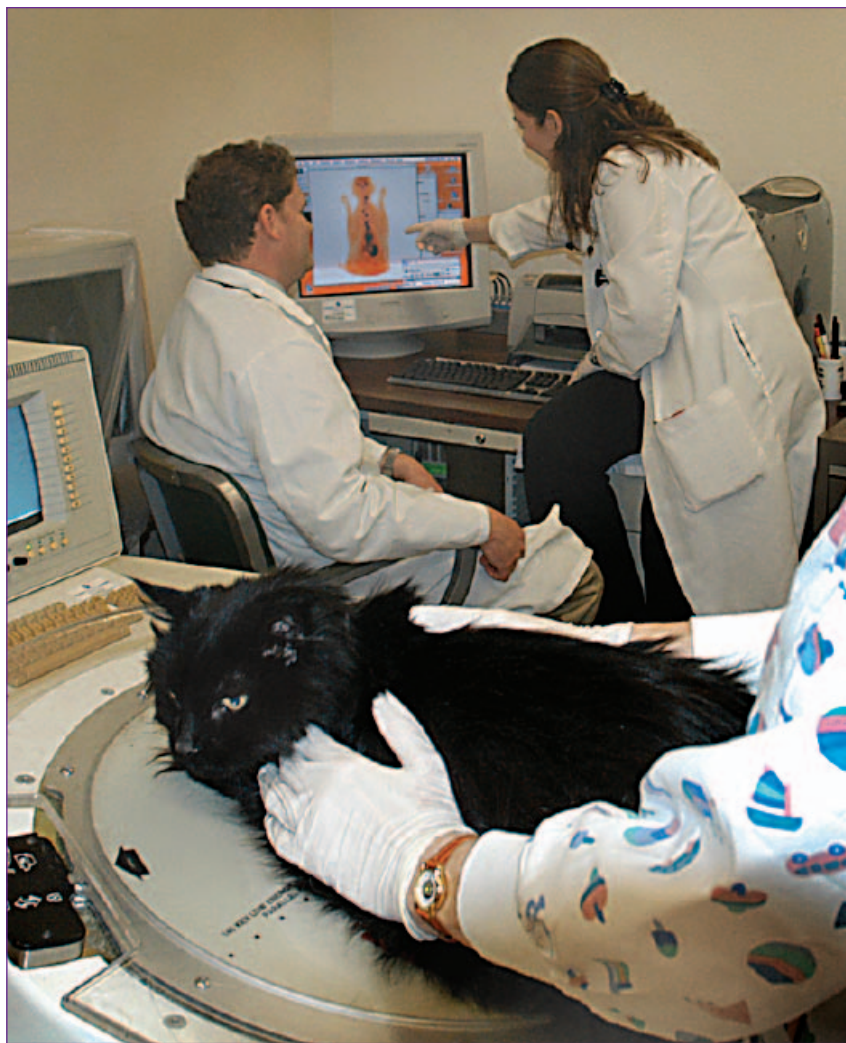

photo by Brennan Engle



photo by Brennan Engle

Above: Ebony received a nuclear scan before the I-131 treatment. His image is on the screen in the background. Dr. Hall-Fonte points out the dark areas, which consist of abnormal thyroid tissue. Following the injection, Ebony was in isolation for 13 days because he was radioactive. When he was discharged, the Gahnstroms couldn't hold him for 10 days.

Dr. Hall-Fonte escorts Bill and Emilie to the Intensive Care Unit to visit Ebony after his surgery in January.



★ IKE ★

ON A MISSION

by Patrice Scott
photos by Brennan Engle

A devastating injury threatened to take a dedicated Fort Riley troop out of action. That's when the Veterinary Medical Teaching Hospital (VMTH) and the military entered into a joint mission to return this mount to the front line. According to his caretakers, Ike, a 13-year-old paint quarter horse, is a workhorse. He loves working and doing. However, an injury in late December took Ike off active duty. "It must have been very difficult for him to watch as the other horses were loaded on trailers headed to Washington, D.C., for President Bush's inauguration," says Capt. Cayla Slusher, commander of the Fort Riley Commanding General's Mounted Color Guard. "He must have wondered why he wasn't going."

The mounted color guard performs at parades, encampments, cavalry demonstrations and special ceremonies across the country. Ike is one of 17 horses and two mules in the unit.

continues on page 15

Above: Ike on official duty before he was injured. He is second from left.

Facing page, small inset: Ike performing jumps during a demonstration. Photos courtesy of Fort Riley.



Capt. Cayla Slusher speaks with Dr. Carolyn Arnold (center) and Maj. Gen. Dennis Hardy when he checks on his mount.

Ike's injury was the result of trauma. He had somehow injured his right front leg, more specifically the pastern joint, which is located between the ankle and hoof. The Fort Riley veterinary staff and soldiers provided initial treatment. "They gave him a steroid injection to relieve the pain and reduce swelling," says Dr. Carolyn Arnold, assistant professor of equine surgery at the VMTH.

On Jan. 12, Ike came to the VMTH for X-rays. "This was a penetrating wound," Dr. Arnold says. "Something slammed into his leg with enough force to puncture the skin and chip the bone." A few weeks later, radiographs showed more deterioration. "They (Fort Riley soldiers) did all the right things and gave Ike every chance to heal, but he wasn't progressing. The damage was too severe, and he was in pain."

Possibly just as painful for Ike was watching the other horses pass by him daily for training. "Ike is athletic. After he was injured, he spent most of the day in a stall," Capt. Slusher says. "We occasionally turned him out in a small paddock so he could have contact with other horses, and they would come up and talk to him. The situation had to be very frustrating for him."

Dr. Arnold and 12 veterinary students traveled to Fort Riley where she gave a presentation on Ike's condition and prognosis to 21 people involved with Ike's care, including soldiers in the mounted color guard unit, the horses' trainer and the Fort Riley veterinary staff. The pastern joint

★ JOINING FORCES

is a very unforgiving joint and arthritis is inevitable, she explains. Since Ike's condition was not going to heal on its own, only two options remained. One was to operate.

"The surgical procedure is technically challenging and correct positioning of implants is crucial," Dr. Arnold explains to the group. "Next, the patient has to go through recovery, and we have to get through any short-term complications. Then we have to get through any long-term complications. It can be an emotional roller coaster. Sometimes we don't know for three or four months following surgery if the patient is going to make it."

The second option was to put Ike down. Capt. Slusher says the idea of destroying Ike was unthinkable. "Ike has an incredible work ethic," she says. "He loves jumping and the thrill of cavalry. His personality meshes with all of the riders and with the training. He has such heart."

The unit's budget was limited so soldiers mounted a campaign for Ike to have the surgery. Before anyone was going to discuss putting their horse down, they were going up the chain of command.

Lt. Col. Don Culver of the north plains district veterinary command and Dr. Roger Fingland, director of the VMTH, joined forces and resources in an effort to save Ike. They



"Ike (left) has an incredible work ethic. He loves jumping and the thrill of cavalry."


—Capt. Cayla Slusher



Above: Maj. Gen. Dennis Hardy came to the stables on post to visit Ike and meet Ike's surgeon, Dr. Carolyn Arnold. There, he presented Drs. Arnold and Finland with a commander's coin to show his appreciation for their efforts.

Right: Drs. Finland (left) and Arnold review radiographs on the hospital's mobile digital X-ray unit. Clearly visible are the two screws across Ike's pastern joint.

Far right, top: It takes a small army to care for Ike as he is discharged on Feb. 23 following two surgeries. Soldiers and hospital faculty and staff stand united in this accomplishment.



★ IKE ★ ON A MISSION

agreed to match funds and work together to contain costs.

Maj. Gen. Dennis Hardy, commanding general of Fort Riley, explains that Ike is an ambassador for the U.S. Army. "The mounted color guard is part of the Army and part of our history," he says. "The partnership we entered into with the teaching hospital is another in a continuing relationship."

Dr. Finland recognized the teaching opportunities. "Simply put, an important representative of the United States military was injured and needed our help to have a chance to return to service," Dr. Finland says. "We have had a long standing, positive relationship with the mounted color guard and have continually embraced the opportunity to support the military in this regard. This was an excellent learning opportunity for our students and residents making it a win-win situation."

Senior student Brandy McGreer was one of many students who participated in Ike's care. "Ike is deserving of this military benefit for performing his duty," Brandy says. "I'm so glad that the hospital could help. It's one way we can say thanks to the military."

Becoming allies

Through this alliance, Ike had cleared his first hurdle: he was going to surgery. On Feb. 16, Ike underwent the two-hour procedure to fuse the joint. "We prepared the joint by removing cartilage and the fracture fragment," Dr. Arnold says. "Two transfixation pins were implanted horizontally across the cannon bone to allow Ike to bear weight on his leg."

Surgeons also took a bone graft from Ike's hip and placed it across the pastern joint because these bone cells help speed fusion. The final step was to put his ankle in a cast.

However, one misstep in recovery quickly turned into a setback. "Ike tried to stand up before he was ready," Dr. Arnold says. "He stumbled and bumped the top transfixation pin on the wall."

Doctors closely monitored Ike and observed he wasn't standing on that leg. He was lame, meaning there was an abnormality in his gait. "These are indications that he was in pain and something was wrong," Dr. Arnold says.

In surgery two days later, surgeons removed Ike's cast and took radiographs. Fortunately, Ike's cannon bone was not fractured. He had bruised the bone, making it painful for him to bear weight on the top transfixation pin. "We removed that pin but we needed to add stability to the leg so we added two screws across the pastern joint," Dr. Arnold says.

Horses and humans have some things in common when it comes to limbs. When indicated, both get implants and casts. The implants used in Ike's leg are the same used



in humans, only larger. The major difference is in recovery. Following surgery, equine patients spend one to two hours in recovery then have to walk to their stall, many times on a broken leg. There is no opportunity for them to convalesce because they have to bear weight on all of their

legs all of the time. When a person's arm or leg is in a cast, they can use crutches or a sling for assistance. No similar device exists for horses so they often develop rub sores.

Five short days following this surgery, Ike was discharged. Patients normally spend six weeks to two months in the hospital post-surgery and are not released while in a cast. Ike was allowed to leave because of the incredible post-op care available to him on post.

"Two soldiers are assigned to Ike with clearly defined

duties," Capt. Slusher says. "Ike is constantly monitored."

A matter of trust

Dr. Arnold has total confidence in the unit soldiers and Fort Riley veterinary staff. "They are perfect clients," she says. "Any little thing you ask them to do, they do it 100 percent. They use an infrared thermometer to take a cast temperature three times a day because an increase in heat could indicate rub sores. The soldiers are committed to Ike, and they are so respectful of the faculty and students. The best thing is to see how bonded they are with Ike."

Once Ike returned home, he received weekly check-ups from Dr. Shane DeWitt, assistant professor of equine field service. "His joint is fusing like it is supposed to," Dr. DeWitt says.

That is a huge accomplishment considering there is no standard outcome with an injured pastern joint. "Our hope is that we save the life of the horse," Dr. Arnold says. "Second, we hope that the horse can have

a wonderful life in the pasture. Third, we hope the horse may be able to return to full athletic function."

A sense of duty

On March 4, Dr. Finland joined Drs. Arnold and DeWitt on a field service visit to Fort Riley where they met with Maj. Gen. Hardy. Ike's condition steadily improved and doctors were optimistic about Ike's future.

Dr. Finland says he's proud of the commitment displayed by the hospital faculty who provided Ike with advanced care. "This extraordinary situation was made possible because our faculty had the expertise to successfully manage Ike's devastating injury. The desire to help alone would not have been adequate. We are able to do what we do because of the talent of our faculty. They are the best of the best."

Maj Gen. Hardy is clearly impressed with the hospital, the faculty and students who have spent months treating Ike. "This is my first experience with the teaching hospital, and we can see the results of your efforts, commitment and expertise," he says as he nods at Ike. "I want to personally thank you (K-State veterinarians, students and staff) for the enormous time you have invested here."

The following week, doctors removed the transfixation pin and changed Ike's cast. Ike cleared another hurdle a month later on April 21 when that cast was removed. He had a rub sore but nothing that concerned doctors. "The surgical site looks great," Dr. Arnold says. "He is right on track." Dr. DeWitt concurs. "Based on his progress, I expect Ike to be able to attempt to return to full activity. He has shown tremendous spirit throughout this ordeal."

Dr. Arnold says that Ike will begin taking short walks that will be increased over time to stimulate healing.

Ike received the care he did because so many people care about him. For the hospital faculty and staff, it was also a way to show appreciation for the services our military provides for us every day.

"We want to take this opportunity to thank all the members of the United States military for doing what they do for us," Dr. Finland says. "We are intensely proud of each of you, and humbled by your selfless commitment. In a very meaningful way, Ike represents what we admire most in each of you." 🐾

Nebraska doctor refers his patients to K-State VMTH

Dr. Jeff Jacobson gives sage advice to clients whose pets need advanced care. "If you are going to do this, go to the best." That's why he refers his patients to the Veterinary Medical Teaching Hospital (VMTH) at K-State.

In 2001, Dr. Jacobson left a successful five-doctor practice after 13 years to open Jacobson Veterinary Clinic in Lincoln, Neb. He believes the teaching hospital is an asset to his growing practice.

"I do all that I can for my patients, but it's comforting knowing that I have an option to offer clients when their pet needs a specialist," Dr. Jacobson says. "The other major benefit is that while I don't have all of the latest equipment available, my patients have access to it through the teaching hospital. It's an amazing facility."

The first time he considered becoming a veterinarian was when his favorite biology teacher encouraged him to think about it. "It certainly combined my love of science with my love for animals."

It would be love, in the end, that led Dr. Jacobson to veterinary medicine. You see, the world was dangerously close to not having a Dr. Jacobson at all. After completing two years at a community college then completing a two-year pre-vet program, he worked in a Nebraska animal disease control lab for five years.

It wasn't until he met his future wife that he contemplated his future and career. "When I met Pam, I picked back up on my dream of being a veterinarian," he says. "She supported me – emotionally, mentally and financially. She worked two jobs to put me through school."

Dr. Jacobson's patients don't know that story. His clients like Tricia Stanczyk just see a great doctor. Tricia's dog, Nickel, is an AKC conformation champion who is having medical problems so Dr. Jacobson referred them to the VMTH. What's unusual is that he cared enough about Nickel and Tricia, who holds special status because she works at the clinic, that he closed his practice for a day so Pam and he could accompany them to Manhattan for Nickel's appointment. "Dr. Jacobson understands that Nickel is my child," Tricia says. "He cares about all of his patients because he understands that our pets are really members of our family."

Not surprisingly, Dr. Jacobson viewed this as an opportunity to help. "Nickel is having a little trouble, and



we know how worried Tricia is about him," Dr. Jacobson says. "We came with her just to give her a little extra support."

It's his willingness to support his patients and clients that impresses his colleagues. "Dr. Jacobson is an exceptional veterinarian," says Dr. Roger Fingland, director of the VMTH. "His commitment and compassion are unparalleled and his support of our hospital is tremendous. We are proud to be associated with Dr. Jacobson and the skilled veterinarians like him who care for animals and their owners in Nebraska."

As a former veterinary student and successful practitioner, Dr. Jacobson believes in giving back to the people who have supported him. "K-State was a positive school. The faculty and staff wanted you to stay in the program and wanted you to succeed," Dr. Jacobson says. "As a veterinarian, referring cases to the teaching hospital is one small way to support the educational process. I also learn from these cases which makes me a better veterinarian."

Dr. Jacobson and his wife, Pam, have two children, Jessica, 17, and Sim, 13, and three dogs and one cat.

Above: Dr. Jeff Jacobson (right) accompanies his patient, Nickel, to the VMTH along with Nickel's owner, Tricia Stanczyk.



Dorothy welcomes Roxie to her new home in September 2004.

by Patrice Scott

A kind word from the past leads to a...

WONDERFUL GIFT

One sentence spoken one-third of a century ago has turned into a \$1 million gift for the Veterinary Medical Teaching Hospital.

John and Dorothy Schwope brought their

standard Poodle, Daisy, to the hospital in the mid-1970s for advanced care. Dr. Jake Mosier was the clinician in charge of Daisy's case. As they were leaving, Dr. Mosier left them with a thought. "If you ever find yourselves in a position to help us with a donation for teaching purposes, please think of us."

Nearly 30 years after that exchange and almost two years after Dr. Mosier's death, the college received a phone call in November 2002 from John and Dorothy's attorney, Stephanie Smith. The couple remembered Dr. Mosier and the care Daisy had received. And they were in a position to help. They were including the teaching hospital in their estate plans by gifting their land in Texas.

Barbara Gunther, John and Dorothy's niece, says the couple shared a love for animals. They married late in life after the deaths of their spouses, and their blended life included their animals. Daisy belonged to John, and Dorothy had two Schnauzers, Missy and Manny.

For several wonderful years, the couple and their animals drove south where they were winter Texans. But as their animals passed away and driving became too taxing for John and Dorothy, they began flying to Texas. Dorothy polled relatives curious to know how their animals handled flights. She longed for another dog.

By now, John and Dorothy had many friends at the College of Veterinary Medicine. Last summer, when they talked of getting another dog, the only discussion was the breed. John wanted a Poodle, but Dorothy wanted a Schnauzer. The college had the answer: a Schnoodle. Yes, a Schnoodle. It's half Schnauzer and half Poodle. And, Dr. Ralph Richardson, dean of the college, happened to know of one that was available to a loving home.

"They were thrilled when we brought Roxie to them," Dean Richardson recalls of that happy September day. "They had toys waiting for her. We took Roxie out in the backyard and laughed as she chased squirrels. When we came inside and Dorothy sat down, Roxie sat beside her. Dorothy just stroked her and stroked her."

There's no doubt that Roxie brought Dorothy enormous joy. "Oh, Dorothy loved that dog," Barbara says. "When I'd call, half of our conversation was about Roxie."

Just as a phone call can bring happy news, it can bring sad news. Stephanie called Dean Richardson to tell him that John, a WWII veteran whose latest battle had been with cancer, died suddenly of heart failure on Jan. 4. He was 93.

"At John's funeral, Dorothy said she was thankful that John was no longer in pain and thankful that she had Roxie," Dean Richardson says. "Several people commented that they expected Dorothy to bring Roxie to the funeral home."

Three weeks later, Dean Richardson's phone rang again. This time it was the shocking news from Stephanie that Dorothy had passed away. "I couldn't believe it," Dean Richardson says in disbelief. "I had just seen her."

With their gift comes the lasting legacy of two giving people who loved each other and animals.

"A gift like this shows the power and depth of the human-animal bond," says Dr. Roger Fingland, director of the teaching hospital. "We often speak of grateful clients who have appreciated the care their animal received in our hospital. The truth is we are grateful to have clients like John and Dorothy. They loved animals and wanted to make the world a better place for students and animals. We will work every day to honor their wishes and remember their legacy." 🐾

Editor's Note: Roxie has a loving home with John and Dorothy's longtime friends in Mission Hills, Kan.

**Kansas State University
Veterinary Medical Teaching Hospital**

Mosier Hall
1800 Denison Ave.
Manhattan, KS 66506

Animal**LIFE**

Susie finds a new home



Dr. Ken Harkin and Susie

Susie, a 13-year-old cat, suddenly lost her home and the warm and loving lap where she spent her days napping when her 92-year-old owner, Thuraline Keith, died.

Thuraline made a bequest to support the College of Veterinary Medicine but no plans existed for Susie's future. Tom Tucker, Thuraline's trustee, discovered Dr. Ken Harkin's Cat Adoption Agency that finds homes for adult cats. Susie had special needs and Dr. Harkin embarked on an exhaustive search to find the right home for her. Today, Susie again has a kind and loving owner in veterinary student Tina Murray.

Thuraline's generous gift to the college was \$267,000. Of that, Tom allotted \$30,000 to the Ken Harkin Cat Adoption Agency, \$60,000 for scholarships in zoological medicine and \$50,000 to the Perpetual Pet Care Program, an endowed gift to pay for Susie's lifelong medical needs. The balance will support college scholarships.

"Thuraline loved animals," Tom says. "I did what I think she would have done. We couldn't have selected a better steward than K-State for her funds."

For more information about Dr. Harkin's adoption agency, please visit our Web site at www.vet.ksu.edu and click on Teaching Hospital. You can read more about it in the spring '04 issue of "AnimalLIFE."



Susie with Tina Murray, her new owner and her benefactor, Tom Tucker

by Patrice Scott
photos by Brennan Engle

The largest veterinary hospital in Kansas and one of the largest in the nation.

Kansas State University Veterinary Medical Teaching Hospital

1800 Denison Ave. • Manhattan, KS 66506

- Small Animal & Exotics: 785.532.5690 • Equine and Agricultural Practices: 785.532.5700
- www.vet.ksu.edu/depts/VMTH